

# ORARISK<sup>®</sup> HSV Sample Report

## Sample, Report

**Date of Birth:** 09/20/1980 (42 yrs)  
**Gender:** Male  
**Patient ID:** 920-G  
**Patient Location:** Test Site A

## Ordering Provider

Ronald McGlennen MD  
 7400 Flying Cloud Drive  
 Suite 150  
 Eden Prairie, MN 55344  
 855-672-5362

## Specimen#:

5989009003  
**Accession#:** 202306-03363  
**Specimen:** Oral Rinse(P)  
**Collected:** 06/05/2023  
**Received:** 06/06/2023 14:29  
**Reported:** 06/07/2023 09:20

## Reason for Testing Related Info

Evaluation of suspicious lesion  
 Not Provided

## Lesion Size Color

2mm x 1mm  
 Mixed  
**Lesion Location(s)** Hard Palate


## MOLECULAR DETECTION OF HERPES SIMPLEX VIRUS (HSV) TYPES 1 AND 2 IN THE OROPHARYNX

### Test Results

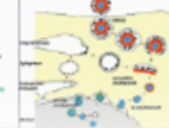
HSV Type 1	Positive
HSV Type 2	Positive

### Infection with Herpes Simplex Viruses Types 1 and 2

#### Structure of the Herpes Simplex Virus



#### Lifecycle of the Herpes Simplex Virus



## Report Includes:



HSV infections are very common, yet can often be mistaken for other causes of oral vesicles, ulcers, and other forms of painful oral and pharyngeal lesions.

Cover

Results & Interpretation

Considerations & Methodology

\*Not available in the state of New York

Learn More at [Oraldna.com](https://www.oraldna.com)

